



CAT PARASITES




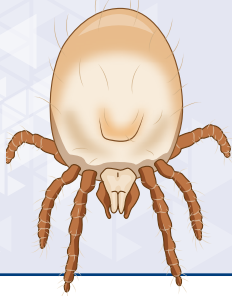
M. Servonnet, E. Tielemans, N. Perier, L. Antoine, F. Beugnet
Global Veterinary Technical Services, Boehringer Ingelheim Animal Health, Lyon, France

TABLE OF CONTENTS

	Acarids	Chiggers (harvest mites) <i>Demodex</i> mites Ear mites Fur mites Mange mites Ticks
	Insects	Fleas Lice
	Digestive Nematodes	Ascarids Hookworms
	Non Digestive Nematodes	Bladder worms Eyeworms Lungworms
	Plathelminths	<i>Dipylidium caninum</i> tapeworm <i>Echinococcus multilocularis</i> tapeworm <i>Taenia</i> tapeworm Other tapeworms
	Digestive protozoans	<i>Giardia</i> <i>Isoospora</i> coccidia <i>Toxoplasma</i> <i>Trichostrongylus axei</i>
	Vector-borne diseases	Heartworm Tick-borne diseases
		Anthelmintic treatment in cats

ACARIDS

CHIGGERS (HARVEST MITES)

Neotrombicula autumnalis, *Eutrombicula alfreddugesi*,
Eutrombicula splendens, *Eutrombicula sarcina*Adults
0.2-0.4 mmEggs
0.2 mm

Visible under the microscope



- There are several species of harvest mites, including: *Neotrombicula autumnalis* (Europe), *Eutrombicula alfreddugesi* (North and South America), *Eutrombicula splendens* (North and South America) and *Eutrombicula sarcina* (Australasia).
- The only parasitic stage is the larva, which may infest wide range of mammals (cats, dogs, rodents, rabbits, humans...), birds, reptiles, and even amphibians.
- Larvae are often **attached to the skin in clusters** and appear as **'orange powder'**. They feed by digesting dermal tissues, similarly to ticks.
- Infestations mostly occur in summer and autumn, but Trombiculids can be seen all year round.



Chigger mite larva.



ACARIDS

CAT ECTOPARASITES

CHIGGERS (HARVEST MITES)

Neotrombicula autumnalis, *Eutrombicula alfreddugesi*,
Eutrombicula splendens, *Eutrombicula sarcina*

BIOLOGY AND MODE OF INFESTATION

Like ticks, **infestation only occurs from the environment**, there is no contamination by direct contact between animals.

Larvae stay attached for a few days (3-4) before leaving their host. Larvae moult to the nymphal stage, nymphs to adults, which are free in the environment.

CLINICAL SIGNS

- **Pruritus and dermal irritation signs.**
- Lesions and clinical signs may persist for several days after mites have fed and left the host.
- Preferred site of infestation: eyelids, ears, face, lips, interocular region, feet and interdigital spaces, pinnae, axillae...

DIAGNOSIS

Based on medical history, time of the year and clinical signs. **Clumps of orange-coloured mites can be seen with the naked eye.** Skin scrapings help to identify mites.

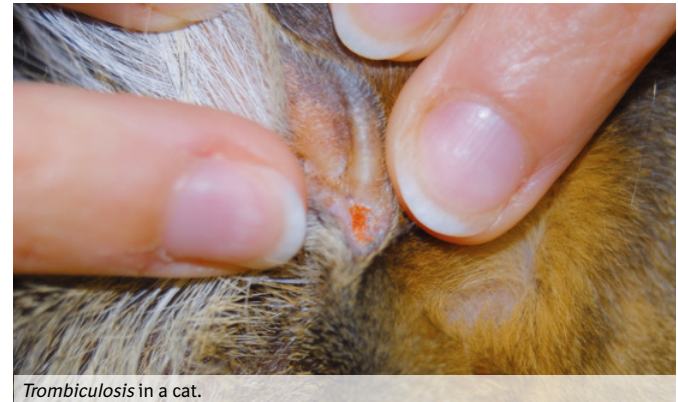ZOONOTIC RISK

Humans can be infested by larvae in the environment like animals.


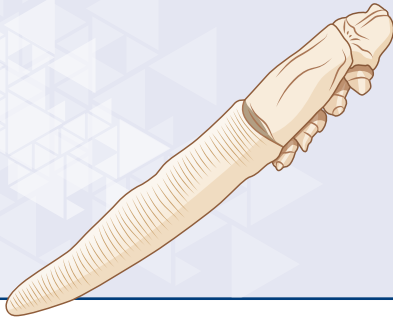
CONTROL MEASURES

TREATMENT

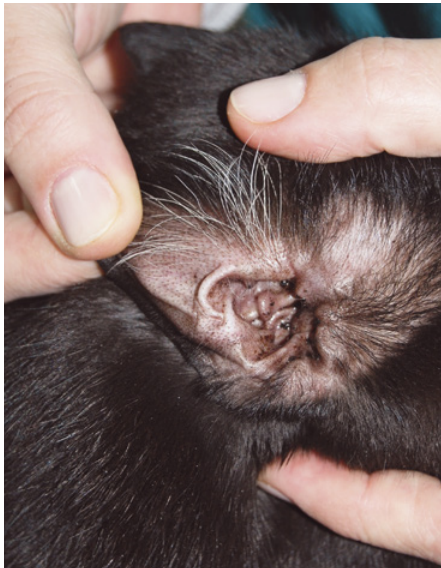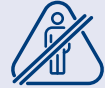No parasiticides are currently registered for this indication, but some acaricides, such as fipronil and isoxazolines, are effective and can be used in cats.



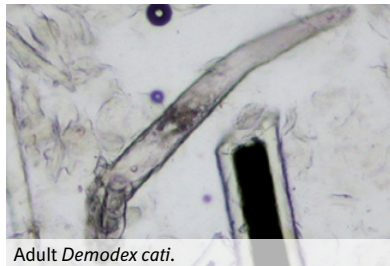
Trombiculosis in a cat.

Adults
0.25-0.3 mm

Visible under the microscope

Eggs
0.05-0.1 mmCeruminous otitis externa due to *Demodex cati*.

- *Demodex* spp. are cigar-shaped mites with atrophied legs.
- *Demodex cati* are commensal mites: **they live in the hair follicles and sebaceous glands**, especially in the eyelids, face, chin and neck, feeding on scales and sebum.
Demodicosis is caused by the uncontrolled proliferation of the mites.
- *Demodex* mites cannot live off their host.
- Demodicosis is a rare skin condition in cats.

Adult *Demodex cati*.

**MODE OF INFESTATION**

Demodex are acquired soon after birth, though direct contact with the queen during milking.

CLINICAL SIGNS

The severity of the clinical signs is usually associated with concurrent primary conditions, such as diabetes mellitus, acquired immunodeficiency (FeLV, FIV infections), hyperadrenocorticism, etc.

Demodex cati is responsible for localised or generalised forms (rare):

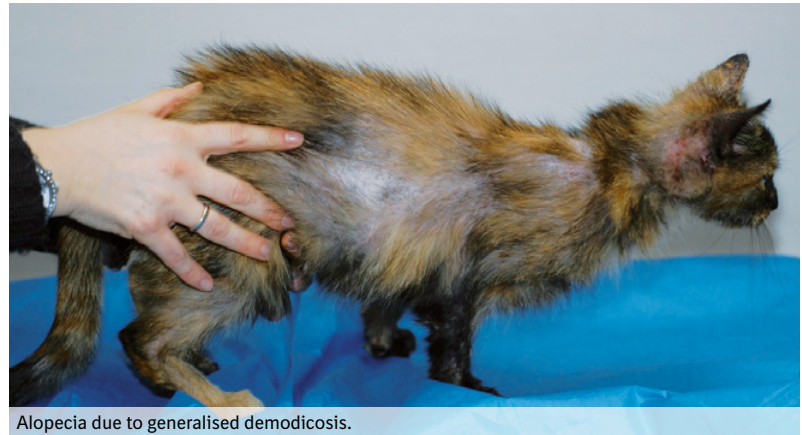- Ceruminous otitis externa (which may or may not be associated with skin disease).
- Pruritus is mild or absent.
- Dermatological signs: alopecia, crusts, seborrhoea, scaling, papules, and miliary dermatitis.

DIAGNOSIS


- Based on the detection of the mites in deep **skin scrapings**.
- A trichogram may be useful in areas that are difficult to scrape, as the mites inhabit hair follicles.

CONTROL MEASURES

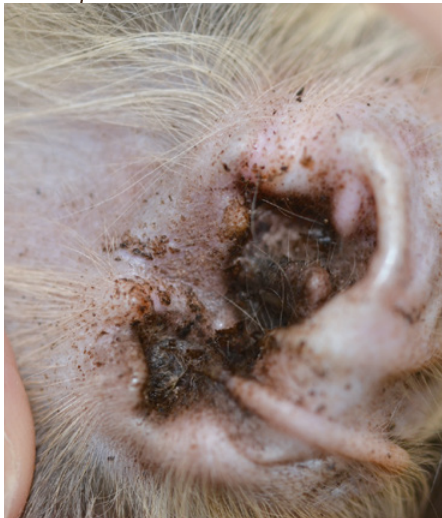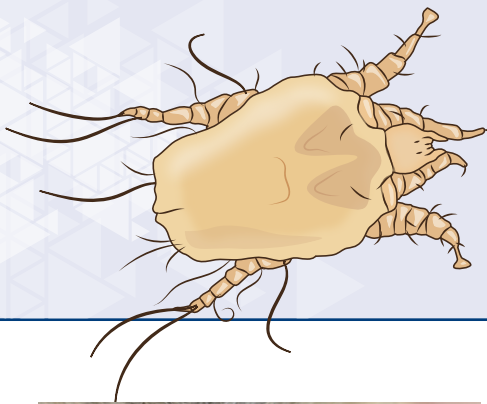
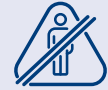No commercialised ectoparasiticides have the indication for feline demodicosis treatment. Based on their great activity in dogs, isoxazoline-based products may be the first choice in cats with demodicosis. It is important to treat the underlying conditions and consider probability of relapses.



Alopecia due to generalised demodicosis.

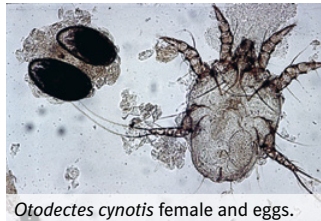
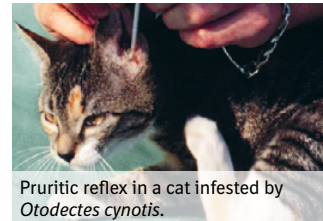Adults
0.5 mm

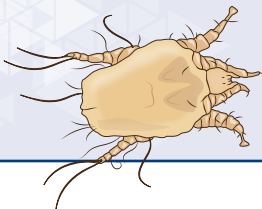
Visible under the microscope

Eggs
0.2 mm

Ceruminous otitis due to ear mite infestation.

- *Otodectes cynotis* is a parasite of cats, dogs and ferrets. It is a **major ectoparasite**, with reported incidences of up to 60% in cats.
- All life stages (eggs, larvae, nymphs and adults) **live permanently in the external ear canal**. Ear mites only leave the ear to infest the other ear, or other hosts.
- They feed on cerumen and inflammatory secretions.
- Ear mites are **highly contagious** between animals.

*Otodectes cynotis* female and eggs.Pruritic reflex in a cat infested by *Otodectes cynotis*.



MODE OF INFESTATION

Direct by close contact with infested cats, dogs and ferrets, or from a contaminated environment (e.g., bedding) even if the mites do not survive more than 3 days out of their host.

CLINICAL SIGNS

- *Otodectes cynotis* is the **primary agent of 50 to 80% of external otitis** in cats.
- *Otodectes cynotis* otitis is often bilateral and characterised by **pruritus and dark cerumen**.
- Self-induced pruritic lesions on and around the ears and secondary bacterial or yeast infections can occur.

DIAGNOSIS

Based on clinical signs and/or visual detection of mites in the ear canal, using an otoscope or **under a microscope using ear canal swabs**. The severity of the otitis does not always correlate to the number of mites.

CONTROL MEASURES

TREATMENT

- **Ear cleaning** to remove the ear wax (cerumen).
- Treat the cat with an approved acaricidal formulation effective against ear mites. Classical formulations were **ear drops** containing organophosphates administered daily for at least 3 weeks. Recent formulations are **systemic spot-on/oral products** containing selamectin, moxidectin, sarolaner, fluralaner, esafoxolaner. A second administration of systemic acaricides may be required one month later to break the parasite life cycle.
- **Treat all the animals** (cats, dogs, ferrets) **of the household** to prevent reinfestation from asymptomatic carriers.


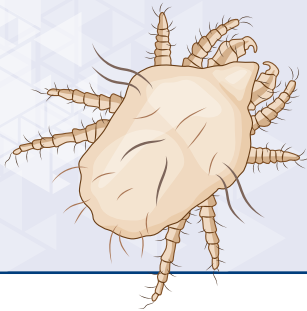
PREVENTION

Preventive treatment may be considered in young kittens and breeding females which often infest their offspring by direct contact.




ACARIDS

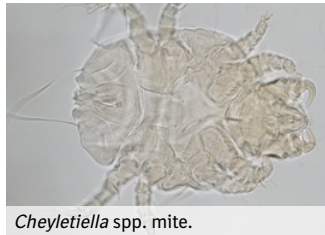FUR MITES

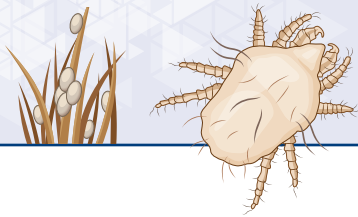
Cheyletiella blackei, *Lynxacarus radovskyi*Adults
0.5 mmEggs
0.1-0.2 mm(rare) only
Cheyletiella blackei

Visible under the microscope



- *Cheyletiella blackei*, also called 'walking drandruff mite', is distributed worldwide and is **more frequent in kittens and cats living in catteries**. This very motile mite is not **strictly host-specific** (it may be transferred between cats, dogs and rabbits) and is highly contagious. It can survive 5 to 6 weeks off the host by preying dust mites.
- *Lynxacarus radovskyi*, also called 'hair-clasping mite' is found in tropical and warm regions. This mite is host-specific and is contagious among cats.
- Both mites **live on the skin surface** and feed on skin debris and epidermis.

*Cheyletiella* spp. mite.*Lynxacarus radovskyi*.

**MODE OF INFESTATION**

Direct contact and contaminated environment.

CLINICAL SIGNS

Cheyletiellosis: Cats can be asymptomatic carriers, especially adults.

Preferred site of infestation: dorsum.

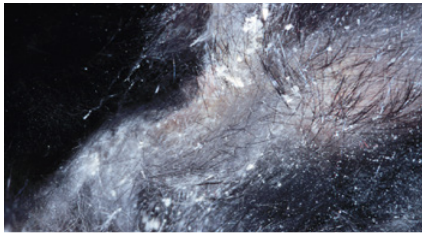
Most common clinical signs: pruritus, skin scaling, erythema, crusted lesions.

***Lynxacarus radovskyi* infestation:** Mostly asymptomatic.

Preferred site of infestation: perineal and tail areas, entire body in case of heavy infestation.

Most common clinical signs: dull and dry coat, scales, 'peppered' appearance, pruritus, hair loss, excoriations.

Severe cases can be associated with feline miliary dermatitis.



Scales caused by Cheyletiellosis.

DIAGNOSIS

Based on **mite identification by microscopy**. Mites are not collected by skin scrapping but through adhesive band test.


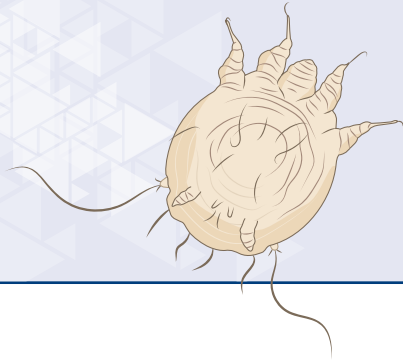
Cheyletiella blackei can also be identified by sitting the cat on a dark surface and grooming some scales: if the dislodged material moves, it is *C. blackei*, hence the name 'walking dandruff mite'.

ZOONOTIC RISK

- *Cheyletiella blackei* is zoonotic: people can acquire transient pruritic and papular rash.
- *Lynxacarus radovskyi* cannot be transmitted to humans.

CONTROL MEASURES**TREATMENT**

- No parasiticides are labelled to treat *L. radovskyi* or *C. blackei* infestations but a number of acaricides licensed for use in cats (e.g., fipronil spray) have been shown to be effective and both parasites seem to be sensitive.
- All the animal of the household must be treated to prevent reinfestation from asymptomatic carriers.



Adults
0.2-0.4 mm



Visible under the microscope

Eggs
0.2 mm




(very rare)

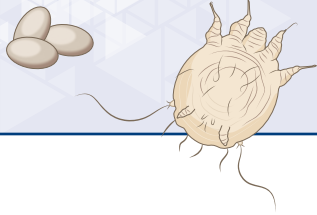


Notoedric mange lesions starting to generalise in a cat.

- Infestations with *Notoedres cati* are rare in pet cats but are common in stray cats. *N. cati* can exceptionally infest other hosts such as foxes and rodents.
- All stages (eggs, larvae, nymphs and adults) live in the **epidermal layers of the skin**: adult females burrow into the epidermis and lay their eggs in tunnels.
- Notoedric mange is **highly contagious between cats**.



Notoedres cati.

**MODE OF INFESTATION**

Direct contact with infested cats or from a contaminated environment (e.g., bedding) where the nymphs and adults may survive up to 3 days.

CLINICAL SIGNS

- Intense pruritus, hair loss, erythema, scaling, crusts, with common secondary bacterial and fungal infections.
- Called 'face mange' the notoedric mange **commonly affects the head** but can spread over the body.
- Untreated cats may become severely debilitated.



Close-up on the face lesions.

DIAGNOSIS

Based on clinical signs and detection of the mites by **deep skin scraping**.

ZOO NOTIC RISK

The mites can temporarily infest humans, causing a pruritic dermatitis with papules, but this occurrence is very rare.

CONTROL MEASURES**TREATMENT**

- Symptomatic treatment of skin disorders.
- Registered systemic acaricidal products are available, containing avermectins/milbemycins and/or isoxazolines.
- Treatment of all in-contact animals.
- Relapses are possible, treatments should be repeated until scrapings are negative and lesions resolved.

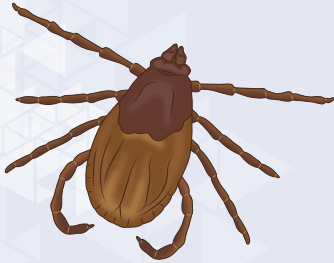
ENVIRONMENT

Regular cleaning/disinfection of the environment by vacuuming and washing bedding throughout the treatment period.

TICKS

ACARIDS

Ixodes spp., *Rhipicephalus* spp., *Amblyomma* spp.,
Dermacentor spp., *Haemaphysalis* spp.



Adults ♂
2-3 mm



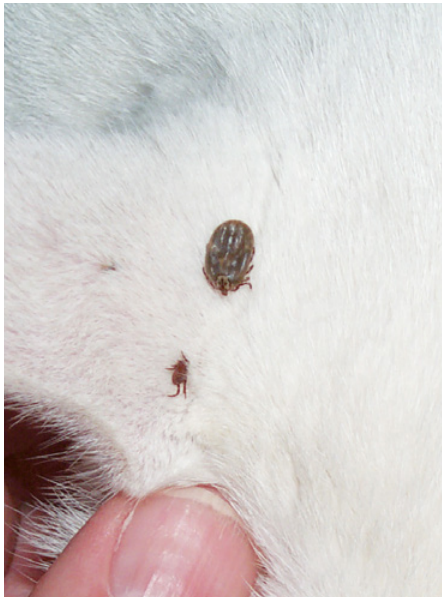Adults ♀
3-4 mm
(unfed)



Adults ♀
8-10 mm
(engorged)



Visible with naked eye



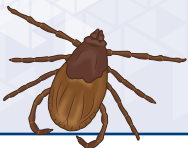- Mammals are mainly infested by Ixodidae, called hard ticks because they have a dorsal chitinous part called scutum. The three stages (larva, nymph and adult) are **hematophagous**. The blood meal lasts 3 to 7 days. The big engorged ticks are the females at the end of their meal.
- Females and males mate on the host. Once they have completed their blood meal, the females fall off their host onto the ground and start laying eggs within 48 to 72 hours. It takes a few days for female ticks to lay around 3000 eggs, before dying.
- Tick infestation can be seasonal in temperate zones, or year-round in warmer regions.



Female ticks lay around 3000 eggs at once.



For more details, see memo card 'Ticks in dogs'.

**ACARIDS****BIOLOGY AND MODE OF INFESTATION**

Ixodidae can be separated into two groups:

- **Questing ticks** (*Ixodes*, *Dermacentor*, *Haemaphysalis*): these ticks climb onto the vegetation during the day, remain immobile and wait for their host to approach before sticking to it.
- **Hunting ticks** (*Amblyomma*, *Rhipicephalus* to a certain extent): these ticks are highly mobile and actively move to their hosts. They can 'run' quite fast.

CLINICAL SIGNS

- Anaemia in case of heavy infestation.
- Inflammatory granulomas in case of improper tick removal.
- Paralysis (caused by paralysis ticks such as *Ixodes holocyclus* in Australia).
- The attachment and feeding are not pruritic and not painful.

TICKS CAN TRANSMIT PATHOGENS TO CATS

- *Cytauxzoon felis*, the agent of cytauxzoonosis.
- Rickettsial agents, such as *Anaplasma phagocytophilum* (granulocytic anaplasmosis).
- *Babesia* spp., the agents of piroplasmosis.

For more details, see memo card 'Tick-borne diseases'.

DIAGNOSIS

Based on **observation of ticks** crawling on haircoat or attached to the skin. During tick seasons and in tick areas, owners must always be advised to search for ticks, even if the antiparasitic treatment is up-to-date.

ZOOONOTIC RISK

Ticks will identically infest humans directly from the environment (but there is no risk of direct transfer from an animal to a human).

CONTROL MEASURES

Examples of active ingredients used in products approved for the treatment and/or prevention of tick infestations in cats:

- Isoxazolines (e.g., esafloxolaner, fluralaner, lotilaner, sarolaner): **systemic acaricidal effect (spot-on or tablet)**
- Phenylpyrazoles (e.g., fipronil): **acaricidal effect through contact (spot-on)**
- Some pyrethroids (e.g., flumethrin): **acaricidal & contact-repellent effects (collar)**. Many pyrethroids may be highly toxic for cats, this is the case for permethrin which is contra-indicated in felines.

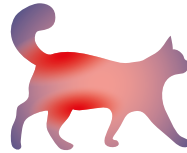
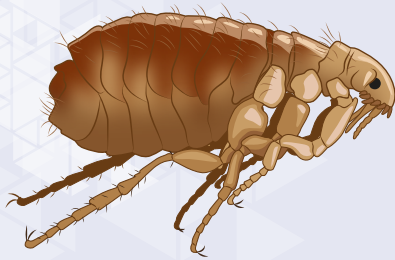
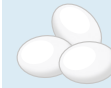TREATMENT OF AN EXISTING TICK INFESTATION

When ticks are diagnosed, they must be immediately and carefully removed with an appropriate device, and an anti-tick treatment should be applied to the animal.

PREVENTION

The tick control is based on regular treatments of the animal with acaricides approved for use in cats.

INSECTS

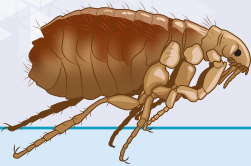
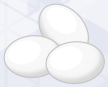FLEAS ^{1/2}
Ctenocephalides felisAdults
3-6 mm
 Visible with naked eye
Eggs
0.5-1 mm

- Fleas are small insects, orange to brown, wingless, laterally compressed, measuring 3-6 mm in length depending on the species, sex and status of engorgement.
- The main genus infesting dogs and cats is *Ctenocephalides*. ***Ctenocephalides felis***, the 'cat flea', is **found worldwide** but prefers warm areas. In cold areas, they have mainly an indoor life cycle (i.e., in house).
- They take their **blood meal on various mammals** (e.g., dogs, cats, rodents, rabbits, humans). **All cats, including indoor cats can be infested with fleas**, but they often manage to limit the level of infestation with their efficient grooming.
- **Adult fleas typically stay on their host** until they die, over a lifetime of 2 to 4 weeks, and rarely move from one host to another.
- Adult female fleas take 4 to 10 blood meals per day, and ingest up to 15 times their weight in blood daily.
- Female fleas lay ~ 25 eggs/day for 30 days (at least 500 eggs over a lifetime).

FLEAS

Ctenocephalides felis

INSECTS




BIOLOGY AND MODE OF INFESTATION

ON THE CAT

Adult fleas are the only parasitic stage found on animals.

Adult




Adult fleas start taking their blood meals on pets very soon after infestation (in 5 to 40 minutes). Females start producing and laying eggs on the host within 36 hours after infestation (sometimes as soon as 24 hours).

IN THE ENVIRONMENT

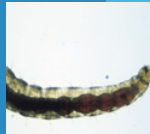All immature stages of fleas live in the environment: indoors (carpets, rugs, cat's bedding, cracks on wooden floor, basement...) and outdoors (e.g., garden). Infested wildlife acts as a reservoir, perpetuating the environmental infestation.

Eggs



Eggs laid in the hair-coat quickly drop off the pet into the environment (i.e., indoor or outdoor).

Larvae

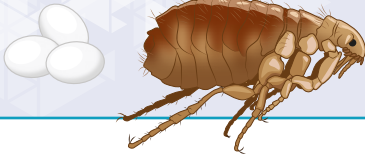

Larvae (L1, L2, L3) feed on organic matters such as flea faeces and skin or other organic debris. If humidity is correct (high sensitivity to dry conditions and UV), they evolve in 7-10 days to form the cocoon.

Pupae



Pupae (pre-emerged fleas) develop in silky and sticky cocoons, which are very **resistant in the environment**, and can survive for 6 to 12 months. Various stimuli induce the hatching of young fleas from cocoons, especially vibrations and shadow from the host. Emerged young fleas move close to the host and jump on it, using their developed third pair of legs. If they fail to infest the host, they will die in a few days.

**CLINICAL SIGNS**

Non-allergic cats: Pruritus, excessive grooming, anaemia in case of severe infestation (more common in kittens, old or debilitated cats).

Allergic cats: They exhibit immune reactions to flea saliva, known as **Flea Allergy Dermatitis (FAD)**.

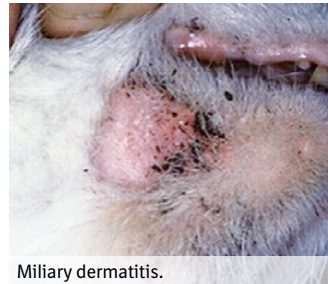FAD signs: Intense pruritus, scratching wounds, excessive grooming, hair loss primarily on the lumbosacral area, miliary dermatitis (numerous papules and scabs on the back and around the neck) and other inflammatory cutaneous disorders.

DIAGNOSIS

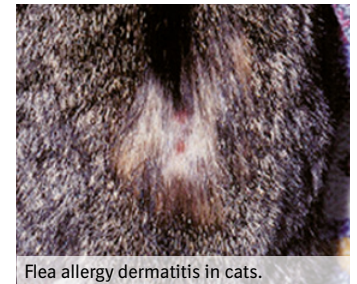Based on **clinical evidence and/or on the observation of fleas or flea faeces in the haircoat**.

Flea faeces appear as a dark 'coma-shaped' grain (up to 1mm in length when intact): when dampened on white paper, a reddish coloration due to the flea's blood diet appears around the 'flea dirt'.

Pet owners may have difficulties to spot fleas on their cat because they are well hidden in the coat and run fast.



Miliary dermatitis.



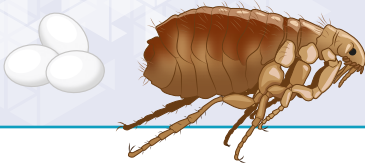
Flea allergy dermatitis in cats.



Flea dirt.



Flea dirt dampened on white paper.



FLEAS CAN TRANSMIT PATHOGENS TO CATS

- *Dipylidium caninum* (see specific memo card).
- *Bartonella henselae*, the agent of the cat scratch disease in humans.
- *Rickettsia felis*, the agent of the flea-borne spotted fever in humans.

ZOONOTIC RISK

The cat flea also feeds on humans and can serve as a vector of *Bartonella henselae* and *Rickettsia felis*.

Fleas can also transmit *Dipylidium caninum* to humans, especially to young children if they accidentally ingest an infected flea.

CONTROL MEASURES

Isoxazolines (e.g., esafloxolaner), phenylpyrazole (e.g., fipronil), selamectin, neonicotinoids (e.g., imidacloprid, dinotefuran), oxadiazine (e.g., indoxacarb) and insect growth regulators are the main active ingredients of products approved for the treatment and/or prevention of flea infestations in cats.

TREATMENT OF AN EXISTING FLEA INFESTATION


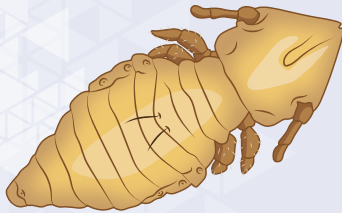
- Treat the cat with an **approved ectoparasiticide for at least 3 months** to get rid of the immature environmental forms. Note that insect growth regulators do not kill adult fleas.
- **Treat all the animals of the household** with an approved ectoparasiticide.
- **Regular cleaning of the environment** (vacuum cleaning and washing bedding) is important to reduce the number of immature flea stages.
- In case of massive infestation, treat the environment with products designed for environmental application (preferably sprays, foggers, etc.).

PREVENTION

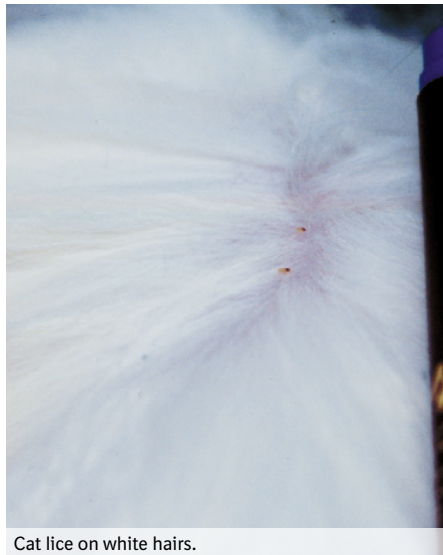
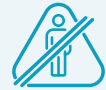It is advisable to implement a flea prevention program to any cat, as most of them are potentially infested and will then infest their environment with immature forms.

INSECTS

LICE


Felicola subrostratusAdults
1-2.5 mmEggs
1 mm

Visible with naked eye



Cat lice on white hairs.

- *Felicola subrostratus* is a **chewing louse** and is **specific to cats**. It does not affect other animal species or humans.
- Adult lice **feed on skin debris** and lay eggs (nits) cemented to hair shafts. The entire life cycle takes place on the cat. Immature and adult lice may survive 1-3 days off their host.
- Louse infestation is rare in pet cats, but common in stray cats.

*Felicola subrostratus*.



MODE OF INFESTATION

Close contact with infested cats, pet bedding, hair brushed or combed.
Indirect infestation can occur but is rare.

CLINICAL SIGNS

Pruritus, scales, crusts, matted coat, hair loss.

DIAGNOSIS

Based on the **observation of nits attached to the base of the hairs**,
or adult lice which move fast and can be difficult to find.
Eggs are whitish, 1 mm long, and fixed to the hair.

CONTROL MEASURES

TREATMENT


- Treat the cat with an approved insecticide effective against lice (e.g., fipronil, selamectin, imidacloprid...).
- Treat all cats of the household to prevent reinfestation.
- Bedding and grooming equipment should be washed.



Close-up on louse eggs.



Nits.



CAT ENDOPARASITES

DIGESTIVE NEMATODES

ASCARIDS ^{1/2}

Toxocara cati, *Toxascaris leonina*



Adults
5-15 cm




Visible with
naked eye

Eggs
70-90
× 65-75 µm



Visible under
the microscope

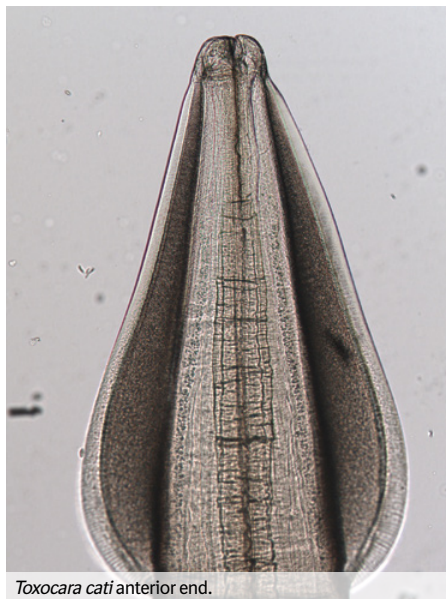

T. leonina

T. cati



(*T. cati* only)



Toxocara cati anterior end.



Adult *Toxocara cati*.

- Ascarids (roundworms) are the **most common intestinal nematodes** infesting cats. They are particularly frequent in kittens.
- Adult worms measure 5 to 15 cm in length and **live in the small intestine** of cats.
- Ascarids are not hematophagous, they consume intestinal nutrients (e.g., glucose, vitamins, calcium and phosphorous).
- *Toxocara cati*, the most common and zoonotic species, causes *larva migrans* in humans.
- *Toxascaris leonina* is less common and is not zoonotic.

DIGESTIVE
NEMATODES

BIOLOGY AND MODE OF INFESTATION

*Toxocara cati***Kittens and young cats (< 6 months):**

- Ingestion of reactivated larvae via the colostrum and milk (transmammary transmission).
- Ingestion of infective eggs from the environment (soiled matters), or ingestion of a paratenic host (e.g., rodents).

Adult cats (> 6 months):

- Ingestion of infective eggs from the environment, or ingestion of a paratenic host containing encysted infective larvae (e.g., rodents).
- Ascarid **eggs are highly** resistant in the environment (up to 5 years).

The *T. cati* larvae undergo distinct migrations depending on the cat's age.

Kittens < 6 months old: entero-pneumo-tracheo-enteral migration.

Infective larvae pass through the intestine wall, migrate to and through the liver, then to the lungs through the lymphatic and venous vessels. When reaching the pulmonary arterioles, they leave the blood vessels, enter the alveoli, migrate up the bronchi and trachea following the mucosal flow and finally reach the pharynx where they are swallowed and access the digestive tract, and transform into adults in the intestine.

Cats > 6 months old: possibility of entero-pneumo-tracheo-enteral migration but also of a somatic migration.

Larvae migrate the same way to the lungs, but do not always enter the alveoli. Instead they may go past the vascular pulmonary filter and get distributed throughout the body by the arterial bloodstream until being stopped at capillary level and get encysted in tissues (mainly in muscles). In case of pregnancy or immune disorder, dormant encysted larvae get reactivated and enter the blood stream, reach the lungs and enter a pneumo-tracheo-enteral cycle to become adults in the intestine, or reach the mammary glands in females.

Toxascaris leonina

- *T. leonina* is more frequent in rural environment, where wild carnivores (e.g., foxes) are present.
- Infestation occurs through the ingestion of infective eggs in the environment, or encysted larvae within a paratenic host (e.g., rodents).

T. leonina develops directly in the small intestine, without any migration.



DIGESTIVE NEMATODES

CAT ENDOPARASITES

ASCARIDS ^{2/2}

Toxocara cati, *Toxascaris leonina*

CLINICAL SIGNS

Toxocara cati

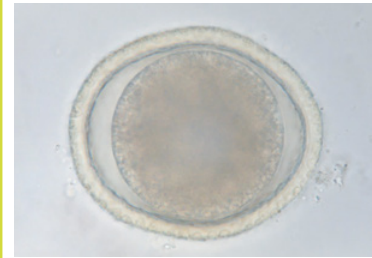
- **Kittens** (under 6 months old) are **more sensitive**.
- **Low burdens** of worms are usually **well tolerated** and asymptomatic.
- In case of mild to **heavy burdens**:
 - **Respiratory disorders**: coughing (due to the tracheal migration of larvae).
 - Failure to thrive, emaciation, dull coat, joint pain.
 - **Intestinal disorders**: pot-belly appearance, vomiting, irregular appetite, diarrhoea (alternating with constipation). Worms can be observed in the vomitus and faeces.
 - Risk of intestinal obstruction in case of heavy infestation.

Toxascaris leonina

- Infestation can occur at any age.
- **Generally well tolerated** and asymptomatic.

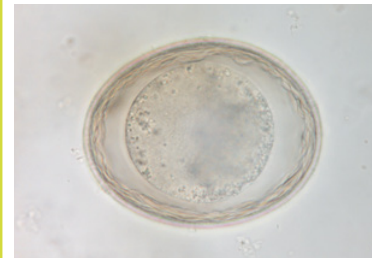DIAGNOSIS

Based on clinical signs and on the **identification of eggs by faecal examination**.



Toxocara cati egg

Globular egg; thick-shelled with an alveolar external layer (thimble-like) and smooth internal layer.
Contents: a single, brownish-black cell filling almost all the shell.



Toxascaris leonina egg

Globular egg; smooth thick shell with concentric layers.
Contents: a single, yellowish-brown cell filling almost all the shell.

DIGESTIVE
NEMATODESZOOBOTIC RISK RELATED TO *TOXOCARA CATI*

- If infective eggs are ingested by humans, the released larvae will migrate through tissues, before dying (visceral *larva migrans*).
- The *larva migrans* phase is usually asymptomatic, the larva will be encysted in an eosinophilic granuloma and killed. In rare cases, it can be medically serious, especially if a larva reaches the brain or the eyes.
Children are at the highest risk because the eggs may be found in their environment, such as public parks and gardens, sand boxes, or private gardens.

CONTROL MEASURES

TREATMENT

The majority of anthelmintics are active against ascarids. It includes pyrantel pamoate, fenbendazole and other benzimidazoles, macrocyclic lactones such as eprinomectin, moxidectin, and milbemycin oxime.

PREVENTION

Regular deworming will prevent cats from being heavily infested and decrease the environmental contamination.

Kittens: deworming should begin at 3 weeks of age and then be repeated every 2 weeks until weaning. Thereafter, kittens should be dewormed once a month until 6 months of age.

Pregnant and lactating queens:

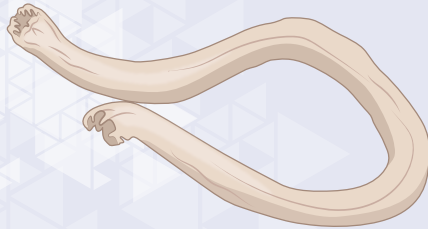- Females should be dewormed during heat.
- Pregnant queens should be dewormed at the start of gestation, 15 days before farrowing, and in the week after farrowing.
- Lactating queens should be treated every two weeks during the milking period until the weaning of kittens.

Adults: frequency of endoparasiticide administration depends on the risk of exposure to ascarids and should be determined by the veterinarian depending on the cat's lifestyle (see the [cat anthelmintic treatment card](#)).

HOOKWORMS

Ancylostoma tubaeforme, *A. braziliense*, *A. ceylanicum*,
Uncinaria stenocephala (rarely).

DIGESTIVE
NEMATODES



Adults
(at necropsy)
1-2 cm

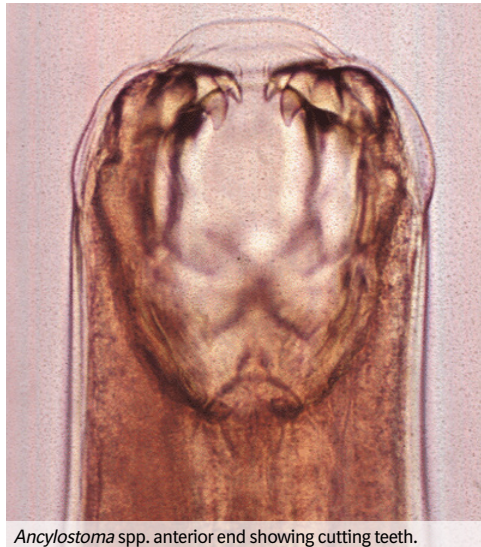

Visible with
naked eye

Eggs
60 x 40 µm

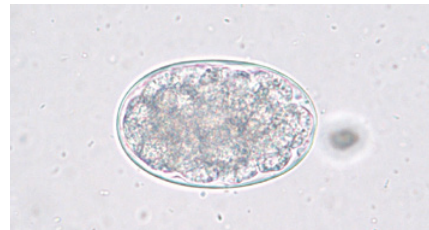

Visible under
the microscope



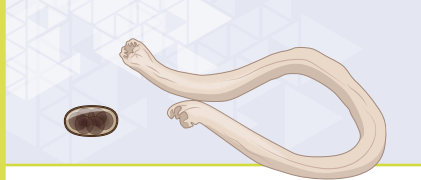Ancylostoma spp. anterior end showing cutting teeth.

- Hookworms, primarily *Ancylostoma tubaeforme*, are common strongylid nematodes infesting cats worldwide. They are particularly common in kittens and stray cats.
- *A. braziliense* and *A. ceylanicum* are found in tropical regions (mainly Central and South America and Asia - Pacific respectively), *Uncinaria stenocephala* is rare in cats and is found in temperate and cold regions worldwide.
- Adult worms measure around 1-2 cm. These blood-feeding nematodes live attached to the mucosa of the small intestine of cats.



Ancylostoma egg.

Oval, colourless egg,
with a thin and smooth shell.
Contents: a morula with 4 to 8 cells.



DIGESTIVE NEMATODES

CAT ENDOPARASITES HOOKWORMS

Ancylostoma tubaeforme, *A. braziliense*, *A. ceylanicum*,
Uncinaria stenocephala (rarely).

BIOLOGY AND MODE OF INFESTATION

- Infestation by direct larval penetration through the skin, or ingestion of soiled matters contaminated with third stage larvae, or ingestion of reactivated larvae via the colostrum and milk.
- After infestation, the hookworm larvae reach the lungs through the lymphatic and venous vessels. Starting from here, they undergo either a pneumo-tracheo-enteral or a somatic migration. Most larvae migrate in the intestine, some may migrate into striated muscle and encyst as dormant larvae (for more details about the migrations, see memocard 'ascarids cats').

CLINICAL SIGNS

- **Cutaneous signs:** pruritus and papular lesions covered with scales on the legs and ventral areas.
- **Respiratory signs:** coughing, nasal discharge.
- **Intestinal disorders:** diarrhoea, bloody diarrhoea.
- **General disorders:** anemia, weight loss, amyotrophy and cachexia in chronic forms.

DIAGNOSIS

Based on the **identification of eggs by faecal examination.**

Diagnosis can be challenging in young kittens as clinical signs appear before eggs are passed in faeces.

ZOO NOTIC RISK

Ancylostoma species are zoonotic parasites causing cutaneous *larva migrans* after penetration through the skin (*Uncinaria* infestation is exceptional in humans).

A. ceylanicum can develop into an adult worm in the intestine of humans.

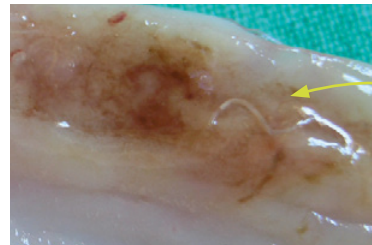
CONTROL MEASURES

TREATMENT

Macrocyclic lactone (e.g., eprinomectin, moxidectin, selamectin), emodepside, benzimidazoles (e.g., fenbendazole) and pyrantel pamoate are approved for the treatment of hookworm infestations in cats.


PREVENTION

- In kittens, frequent deworming is essential as the prepatent period of hookworm may be as short as 14 days.
- Kittens and their mother should be treated every 2 weeks, from 2-3 to 8 weeks of age.
- Pregnant queens should be dewormed 15 days before giving birth.
- In adults, frequency of deworming depends on the risk of exposure to hookworms and should be determined by the veterinarian depending on the cat's lifestyle (see the cat anthelmintic treatment card).



Ancylostoma tubaeforme
attached to the mucosa

Lesion of ancylostomosis in a cat's intestine




CAT ENDOPARASITES

NON DIGESTIVE
NEMATODES

BLADDER WORMS

Capillaria plica, *Capillaria feliscati*



Adults
(at necropsy)
1-2 cm



Visible with
naked eye

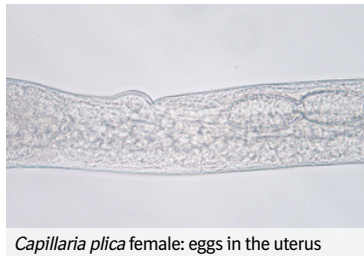Eggs
55-70 x 30 µm



Visible under
the microscope



- *Capillaria* spp. are thin whitish nematodes measuring 1-2 cm long.
- Adult worms are present in the wall of the **urinary bladder** and females lay their eggs in the bladder lumen. These are then expelled in the urine. The **eggs are resistant in the environment** and may be ingested by earthworm.
- Bladder capillariosis is common in wild and stray cats.



Capillaria plica female: eggs in the uterus

BLADDER WORMS

*Capillaria plica, Capillari feliscati*NON DIGESTIVE
NEMATODES

MODE OF INFESTATION

Ingestion of **earthworms** that harbour the infective first-stage larvae.

CLINICAL SIGNS

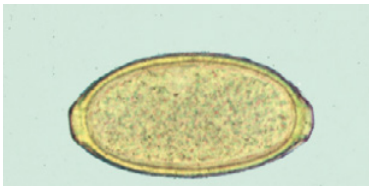- Asymptomatic form is frequent.
- Signs of urinary infection (chronic cystitis): frequent and painful urination, blood in urine.

DIAGNOSIS

- Clinical diagnosis is difficult and bladder capillariosis is **often misdiagnosed**. It should be suspected in cases of chronic cystitis refractory to classical treatments.
- Diagnosis is based on the **identification of *Capillaria* eggs in urinary sediment**.

***Capillaria* egg**

Eggs are elongated, with a smooth, thick shell and a shallow polar prominence at each end.
Contents: a single cell.



CONTROL MEASURES

TREATMENT

- Topical formulations containing **epinomectin** are licensed for the treatment of *C. plica* infestations in cats.
- The off-label use of other macrocyclic lactones has been demonstrated to be effective.


PREVENTION

Since cats with outdoor access presumably prey on potential hosts of *Capillaria* spp., accidental infections cannot be completely avoided.

NON DIGESTIVE
NEMATODES

EYEWORMS

Thelazia callipaeda, *Thelazia californiensis*



Adults
7-17 mm

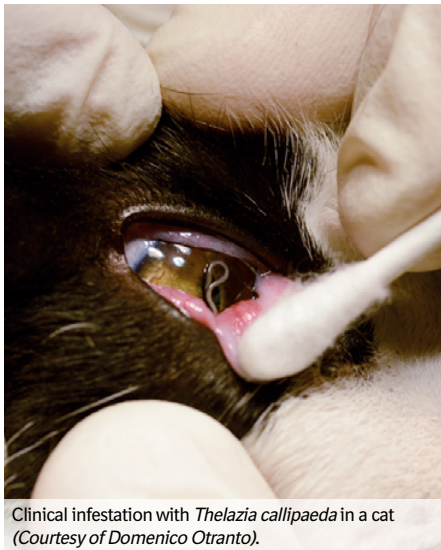
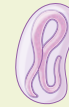
Visible with
naked eye

Larvae
300-400 µm

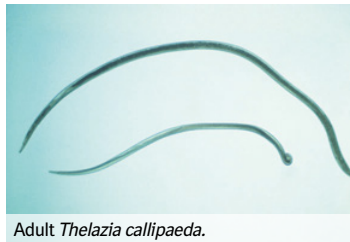

Visible under
the microscope

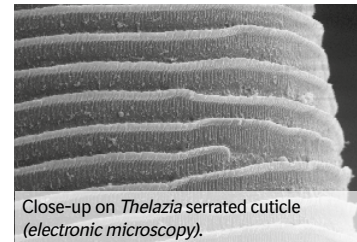


Clinical infestation with *Thelazia callipaeda* in a cat
(Courtesy of Domenico Otranto).

- *Thelazia* spp. is a whitish filiform nematode measuring 7 to 17 mm long.
- *Thelazia callipaeda* is distributed in Europe and Asia, while *Thelazia californiensis* is found in the Americas.
- Adult eyeworms live in the cat's conjunctival sacs and females release first stage larvae in the lacrimal secretions.
- Thelaziosis is due to the presence of adult worms as foreign bodies but also to their irritating serrated cuticle.



Adult *Thelazia callipaeda*.



Close-up on *Thelazia* serrated cuticle
(electronic microscopy).



NON DIGESTIVE NEMATODES

CAT ENDOPARASITES

EYEWORMS

Thelazia callipaeda, Thelazia californiensis

MODE OF INFESTATION

Fruit flies are the intermediate host: they get infested by first stage larvae when feeding on lacrimal secretions, and infest cats with third stage larvae when feeding again.



Fruit flies feed on lacrimal secretions and transmit *Thelazia* spp. to cats while feeding.
Courtesy of Domenico Otranto

CLINICAL SIGNS

- Uni- or bilateral **conjunctivitis**.
- Ocular signs of irritation: eye twitching, tearing, eye redness.
- Secondary bacterial infections are possible.

DIAGNOSIS

Visual identification of whitish nematodes on the eyes and in lacrimal sacs.

ZOONOTIC RISK

Thelazia spp. can also be transmitted to humans by fruit flies. There is no direct transmission from cat to human.

CONTROL MEASURES

TREATMENT

Removal of worms with clamps or cotton swab, followed by eye flushing.

A macrocyclic lactone-based product is indicated for the treatment of adult worm infestation.

PREVENTION

No parasiticides are currently registered for this indication in cats, but monthly administrations of macrocyclic lactones may be effective.

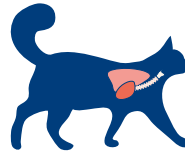


NON DIGESTIVE NEMATODES

CAT ENDOPARASITES

LUNGWORMS

Aelurostrongylus abstrusus,
Troglostrongylus brevior, *Capillaria aerophila*



Adults
(at necropsy)
4-24 mm



Visible with
naked eye

Capillariid eggs
65 x 30-40µm

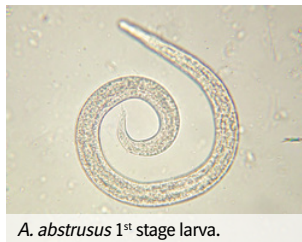

Visible under the microscope

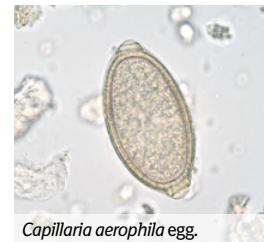Strongylid 1st
stage larvae
300-400µm



- ***Aelurostrongylus abstrusus* is the most common lungworm in cats.** It is a thin nematode measuring 4-10 mm long. Adult worms are located in the alveoli.
- ***Troglostrongylus* spp.** are bigger strongylid with a body length ranging from 5 to 24 mm. Adult worms live in bronchioles and bronchi (*T. brevior*).
- ***Capillaria aerophila*** are filamentous Capillariid worms that live beneath the epithelium of bronchi and trachea.
- Lungworm infestations are **underdiagnosed but are not rare** in cats with outdoor activities.



A. abstrusus 1st stage larva.



Capillaria aerophila egg.



NON DIGESTIVE NEMATODES

CAT ENDOPARASITES LUNGWORMS

Aelurostrongylus abstrusus,
Troglostrongylus brevior, *Capillaria aerophila*

MODE OF INFESTATION

Aelurostrongylus abstrusus, *Troglostrongylus brevior*

- Ingestion of intermediate hosts (snails, slugs...).
- Ingestion of paratenic hosts (rodents, lizards, birds...).

Capillaria aerophila

- Ingestion of embryonated eggs in the environment.

CLINICAL SIGNS

- In case of **low burden**, common in adult cats, the infestation is often asymptomatic.
- In case of **mild to heavy burden**, more common in kittens and young cats:
 - **Respiratory signs:** sneezing, nasal discharge, dyspnoea, respiratory distress, mild to intense cough, bronchopneumonia.
 - **General signs:** lethargy, depression, weight loss, complicated bronchopneumonia, respiratory failure and death.

DIAGNOSIS

Aelurostrongylus abstrusus, *Troglostrongylus brevior*

- Larvae identification by microscopic coproscopy (Baermann technique).
- Molecular methods have been developed to distinguish and identify larvae of *A. abstrusus* and *T. brevior*.

Capillaria aerophila

- Egg identification by microscopic coproscopy.

CONTROL MEASURES

TREATMENT

Symptomatic treatment: anti-cough and antibiotic treatment may be administered in case of secondary bacterial infection.

Specific treatment:

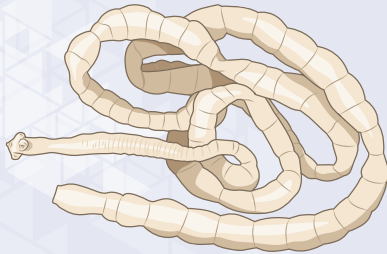
- **Topical formulations** containing **eprinomectin** are licensed for the treatment of *A. abstrusus* and *T. brevior* infestations.
- **Other topical formulations** (e.g., moxidectin, emodepside) have also been demonstrated to be effective.

PREVENTION

Regular deworming of cats with **anthelmintics** is essential to prevent heavy lungworm infestations. Frequency of endoparasiticide administration depends on the risk of exposure and should be determined by the veterinarian depending on the cat's lifestyle.

PLATHELMINTHS

DIPYLIDIUM CANINUM TAPEWORM



Adults
(or proglottids)
15-70 cm
(0.5-1 cm)



Visible with
naked eye

Eggs
50 × 40 µm



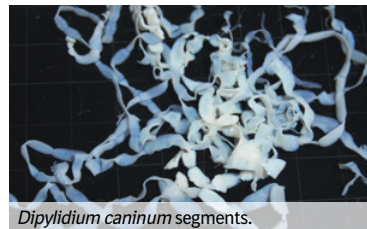
Visible under
the microscope



(rare)



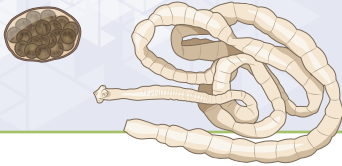- *Dipylidium caninum* is the most frequent tapeworms in pets worldwide.
- *Dipylidium caninum* are flat, white and segmented worms (i.e., cestode class). They measure 15 to 70 cm long, 2 to 3 mm wide.
- Adults live in the cat's small intestine. The **most common intermediate host** of the life cycle of *D. caninum* is the **flea**, and the other one is the louse.
- Genetic and biological studies have demonstrated that two distinct genotypes exist worldwide, one infecting dogs, and the other infecting cats, with no hybridisation. The cat genotype has been proposed as a new species, *Dipylidium felinum*, to differentiate it from the canine genotype.



Dipylidium caninum segments.

DIPYLIDIUM CANINUM TAPEWORM

PLATHELMINTHS



BIOLOGY AND MODE OF INFESTATION

- **Cats get infested by ingesting an infected flea** (i.e., containing a cysticercoid larva of *Dipylidium*) **during grooming**. The tapeworm will develop within 5-6 weeks. Mature tapeworms eliminate continuously the latest segments (or proglottids) which contain eggs in egg packets (around 10-20 egg packets of 20-30 eggs each).
- Cats very rarely excrete gravid segments in faeces. These segments are active and they usually move out of the anus and around the perianal region by themselves. The segments (measuring 5 mm in length) fall off in the environment (e.g., on the floor, in carpets, sofa, pet bedding...). Over time, they desiccate and shrivel up, resembling whitish, uncooked rice grains of 3-5 mm long.
- Proglottids and/or egg packets (oviferous capsules) are thus present in the same places as flea larvae which will ingest them as food. The tapeworm larva first develops in the flea larva and becomes fully infective around 36 hours after infestation of the host by the young flea.

CLINICAL SIGNS

- **Generally well tolerated.**
- **Intestinal disorders:** perianal itching, licking and nibbling at the base of the tail, variable appetite, diarrhoea.
- **General signs:** weight loss (in kittens or severely infested cats).

DIAGNOSIS

- Based on the **observation of proglottids** by macroscopic examination **in the perianal region**, on the ground or, less commonly in the faeces.
- Eggs can exceptionally be found in the faeces if a segment has been destroyed before being expelled.

Fresh *Dipylidium* mature proglottids.

ZOOBOTIC RISK

The accidental ingestion of a flea by a child, which is unusual, can result in a human case of dipylidiosis.

CONTROL MEASURES

TREATMENT

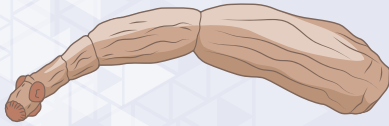- **Praziquantel** is the cestodicide of choice to treat cats against tapeworms.
- Treatment against *D. caninum* is advisable in cats with flea infestations.

PREVENTION

- Regular use of insecticides for flea control will limit the risk of infestation with *D. caninum*. (see memo card 'Fleas').
- Frequency of cestodicide administration depends on the risk of exposure to tapeworms and should be determined by the veterinarian depending on the cat's lifestyle (see the cat anthelmintic treatment card).



PLATHELMINTHS

*ECHINOCOCCUS
MULTILOCULARIS* TAPEWORM

Adults
(at necropsy)
1.5-5 mm

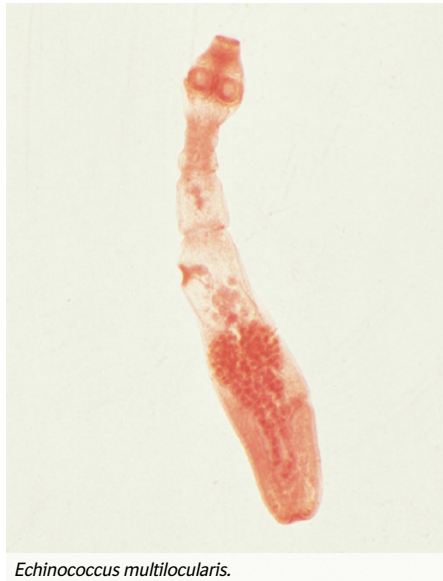

Visible with
naked eye

Eggs
30-40
× 20-30 µm

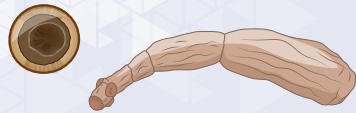

Visible under
the microscope



Echinococcus multilocularis.

- *Echinococcus multilocularis* is a very small tapeworm (i.e., cestode class) belonging to the family of Taeniidae. It is firstly a parasite of wild canids, primarily of foxes.
- Cats can be infested by *E. multilocularis* but are a poorly adapted host compared to foxes and dogs.
- Adult worms measure 1.5 to 5 mm long and attach to the wall of the **small intestine**. They survive approximately 4 months.
- Infestations in cats are usually limited, when they are classically massive in foxes, involving several hundred cestodes.
- Infested definitive hosts shed mature proglottids containing **eggs** which are **highly resistant in the environment** and highly infective for intermediate hosts (rodents, especially voles), or aberrant intermediate hosts (human).



PLATHELMINTHS

CAT ENDOPARASITES

ECHINOCOCCUS MULTILOCULARIS TAPEWORM

BIOLOGY AND MODE OF INFESTATION

- Ingestion of infested intermediate hosts (**rodents**, mainly voles).
- Development of the adult tapeworm within 3-4 weeks in the small intestine.
- The tapeworm contains only one mature proglottid formed at a time.

CLINICAL SIGNS

- **Generally, very well tolerated.**
- Rarely, diarrhoea can be observed.

DIAGNOSIS

Eggs are rarely seen in coproscopy as mature proglottids (of 2-3 mm) are eliminated, and these eggs cannot be differentiated from other Taeniidae eggs.

The diagnosis is therefore based on the detection of:

- Parasite antigens in faeces (coproantigens, for which ELISA kits are available).
- Specific DNA fragments in faeces, using gene amplification techniques (PCR).

ZOONOTIC RISK

- *E. multilocularis* is the agent of multilocular or alveolar echinococcosis, a major zoonosis in humans leading to death in about 30-50% of cases.

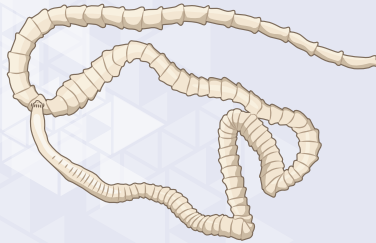CONTROL MEASURES

TREATMENT

Praziquantel is the cestodicide of choice to treat cats against tapeworms, including *Echinococcus* infestations.

PREVENTION

Frequency of cestodicide administration depends on the risk of exposure to *E. multilocularis* and should be determined by the veterinarian depending on the cat's lifestyle ([see the cat anthelmintic treatment card](#)).



Adults
(or proglottids)
60 cm
(8-15 × 5-6 mm)

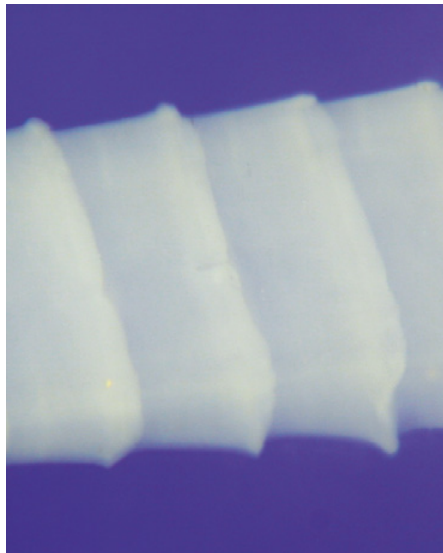
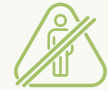

Visible with
naked eye

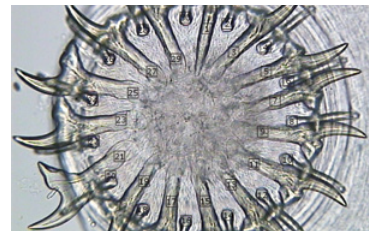
Eggs
30-40
× 20-30 μm



Visible under
the microscope



Taenia taeniaeformis proglottids.



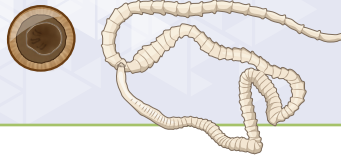Taenia taeniaeformis rostellum.
The rostellum, based on the scolex,
is an organ of attachment
of tapeworms.

- *Taenia taeniaeformis* is a tapeworm (i.e., adult cestode) belonging to the family of Taeniidae and specific of felids as definitive hosts.
- It is **common worldwide**, in cats with **outdoor activities and/or preying on rodents**.
- *T. taeniaeformis* measure around 60 cm long, and live in the cat's small intestine. They are **attached to the gut wall** by means of their scolex and **absorb nutrients** from their host.

TAENIA TAPEWORM

Taenia taeniaeformis

PLATHELMINTHS



BIOLOGY AND MODE OF INFESTATION

- The cats get infested through the ingestion of **intermediate hosts (rodents, mainly mice)**, harbouring the infective larvae.
- The larvae evolve in adult tapeworms in about 6 weeks. The mature tapeworm eliminates gravid segments (also called ‘proglottids’) which are shed in the faeces, or pass out of the anus by independent movements.
- The segments disintegrate in the external environment, **releasing thousands of very resistant eggs** that can remain infective for up to a year.
- The life cycle takes 6-8 weeks to complete.

CLINICAL SIGNS

- Generally well tolerated.
- **Moderate intestinal disorders:** varying appetite (generally increased), colic, diarrhoea.
- In untreated cats, **massive infestation** may be observed and lead to **intestinal obstruction**.

DIAGNOSIS

- Based on the **identification of the segments** in the faeces.
- Microscopic faecal examination for eggs will be negative if no segments have been fragmented in the gastro-intestinal tract.

Tapeworm infestation is challenging and **underdiagnosed** due to **intermittent shedding of proglottids** and **poor sensitivity of the microscopic coproscopy**.

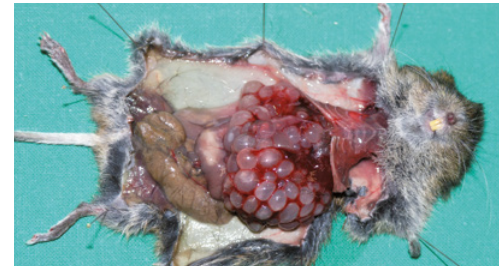CONTROL MEASURES

TREATMENT

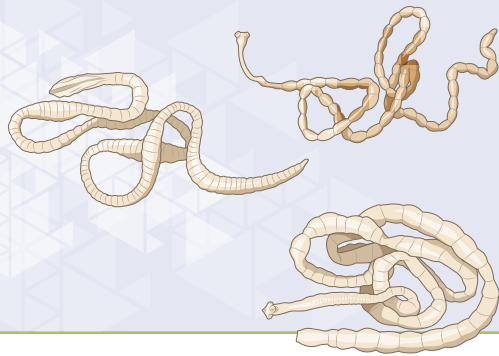
Praziquantel is the cestodicide of choice to treat cats against tapeworms.

PREVENTION

Frequency of cestodicide administration depends on the risk of exposure to tapeworms and should be determined by the veterinarian depending on the cat's lifestyle ([see the cat anthelmintic treatment card](#)).



Taenia taeniaeformis larvae in a vole.



Adults
(or proglottids)

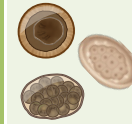


Visible with
naked eye

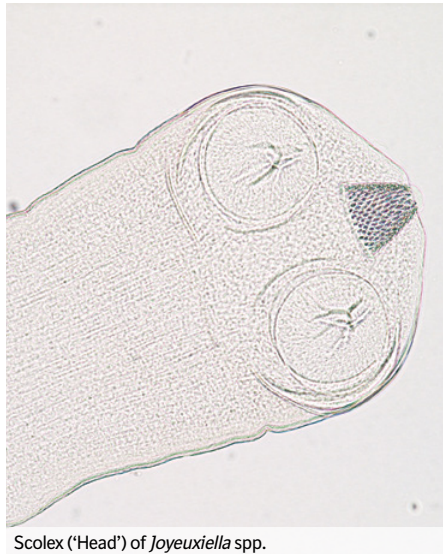
Eggs



Visible under
the microscope



(Some species only)

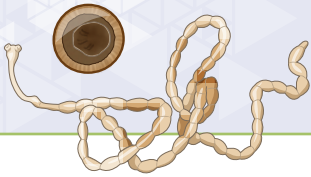


Scolex ('Head') of *Joyeuxiella* spp.

Beside *Dipylidium* and *Taenia* tapeworms, other much rarer tapeworms can infest cats

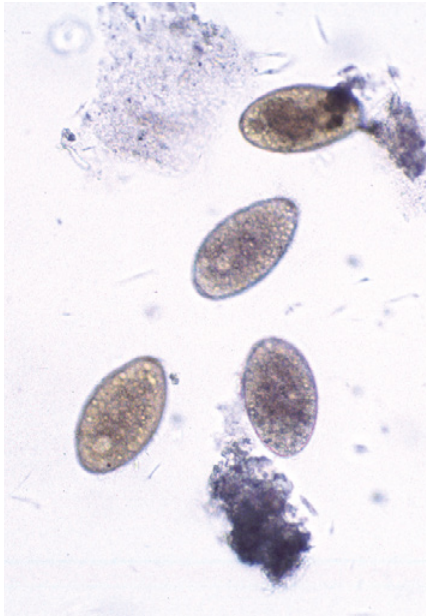
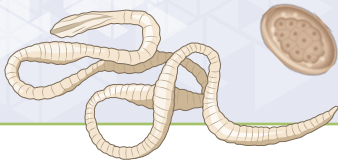
Diplopylidium spp. and *Joyeuxiella* spp.

- These tapeworms are **very similar in morphology to *Dipylidium caninum*** (see memo card *D. caninum*) but smaller in size.
- Their **intermediate hosts are reptiles** (snakes and lizards).
- They are generally well tolerated.
- Praziquantel is the cestodicide of choice to treat infestations in cats.



Mesocestoides lineatus and *Mesocestoides litteratus*

- These tapeworms measure **20-50 cm** in length. Their segments are as wide as they are long and have rounded edges.
- Carnivores become infested by ingesting the second **intermediate hosts** which are insectivorous vertebrates (**amphibians, reptiles or birds**) infested by the tetrathyridium larvae. The first intermediate hosts are arthropods (insects).
- Clinically, the infestation can be asymptomatic, but in some cases, the **carnivores can act as intermediate hosts** with a multiplication of larvae in the abdominal cavity. It may evolve to a **peritonitis**.
- Diagnosis is often made accidentally during surgery when lots of larvae looking like semolina are visible.
- **Praziquantel** has been used successfully to treat *Mesocestoides* spp. infestations.



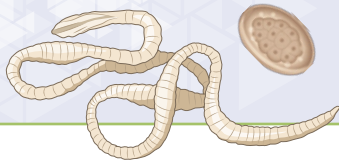
Dibothriocephalus spp. eggs.

*Tocostoma = egg-laying orifice in segments.

Dibothriocephalus latus and *Spirometra* spp. (‘broad tapeworms’)

Dibothriocephalus latus

- *D. latus* (formerly *Diphyllobothrium latum*) is found in the lake regions of Europe. Other *Dibothriocephalus* species are **described worldwide**.
- Cats get infested by **eating freshwater fishes** (second intermediate hosts or paratenic hosts) harbouring plerocercoid larvae. The first intermediate hosts are small crustaceans.
- *D. latus* is probably the **most pathogenic tapeworm**: it causes intestinal disorders, abdominal discomfort, diarrhoea and anaemia.
- **Diagnosis** is based on the identification of **eggs in the faeces**. Proglottid shedding is rare: eggs are eliminated directly through a tocostoma*.
- **Praziquantel** has been used successfully to treat *Dibothriocephalus* spp. in cats, but it must be used at **8 times the regular dose**, as in humans.
- Preventing infestation in cats includes avoiding to feed them with raw fish or with the viscera of fishes caught in lakes.
- *D. latus* is **zoonotic** and medically significant, due to the size of the adults (up to 12 meters in length), and the depletion in vitamine B12 inducing anaemia.



Spirometra spp.

- Cestodes of the *Spirometra* genus, especially *Spirometra mansoni*, are **mainly found in Asia and in the Pacific islands**.
- **Cats become infested by ingesting amphibians** (second intermediate hosts or paratenic hosts) infested by the plerocercoid larvae. The first intermediate hosts are crustaceans.
- Intestinal infestations of cats with *Spirometra* spp. rarely cause any disturbance.
- Like for *Dibothriocephalus*, **praziquantel** has been used successfully at **high doses** to treat infestations.
- ***Spirometra* tapeworms are zoonotic parasites.** Humans become infested by drinking water, by eating tissues of an intermediate host, or by direct contact with the amphibian skin. These tapeworms do not develop in humans, but the plerocercoid larvae induce a larva migrans that can be severe.

DIGESTIVE
PROTOZOANS

GIARDIA
Giardia duodenalis



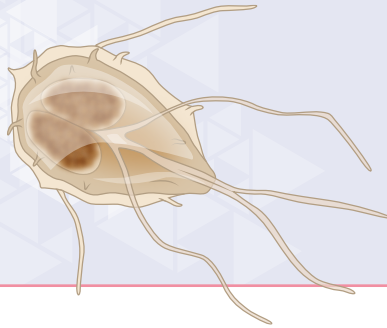
Mobile stages
(rarely seen)
6-8 × 12-15 μm



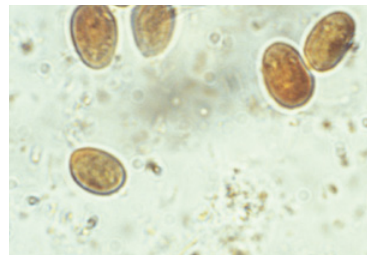
Cysts
8 × 12 μm



Visible under the microscope

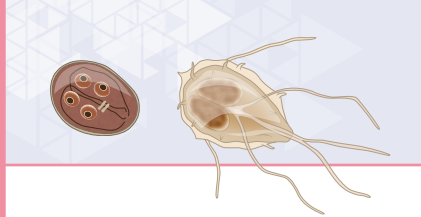


- *Giardia* spp. are protozoans belonging to the class of flagellates, infecting the epithelium of the small intestine (and stomach for a few species).
- *Giardia duodenalis* (syn. *Giardia intestinalis*) is mostly found in the duodenum, jejunum and anterior ileum. *Giardia* are fixed to the surface of the brush border of intestinal cells, mainly at the base of the villi.
- This parasite has two active stages:
 - Trophozoite, which is the motile stage in the small intestine,
 - Cyst, which is the resistant stage eliminated in the environment.



Giardia cysts (Lugol's iodine stain).

Cysts are more or less rounded with a thin and smooth shell. Lugol's iodine stain make *them* take on a very clear orange hue.

**BIOLOGY AND MODE OF INFECTION**

- The infection occurs by the **ingestion of *Giardia* cysts** from fecal-contaminated water, food, fomites or through self-grooming.
- After ingestion, the **cysts hatch and release two trophozoites**. These trophozoites form a 'carpet' on the intestinal epithelium and **multiply by binary division**. Some trophozoites may form cysts that are detectable in faeces 7 days after infection.

CLINICAL SIGNS

- Giardiasis is more common in cats with altered immunity.
- Young cats (from weaning to 2 years old) are more sensitive than adults.
- Cats can be asymptomatic carriers or present a maldigestion-malabsorption syndrome, with **yellowish, fatty, pasty, foul-smelling, chronic diarrhoea**.

DIAGNOSIS

- **Identification of *Giardia* cysts** in the faeces through coproscopy. Clinical giardiasis is related to intense proliferation of the protozoans and coproscopy is sensitive in that case. For healthy carriers, cysts are shed intermittently. If the faecal examination is negative, it may be a false negative result and needs to be repeated. A negative result does not mean that the cat is not infected.
- **Direct immunofluorescence assay (IFA)**.
- **ELISA kit** to detect the coproantigens in faecal matter from infected individuals.

ZOOBOTIC RISK

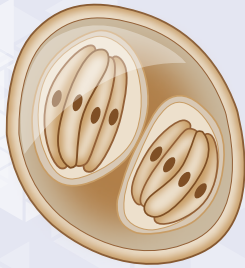
Giardia duodenalis may infect humans. *Giardia* are genetically divided in genotypes called Assemblages. Assemblages are more or less adapted to some species, and do not have all the same zoonotic potential.

CONTROL MEASURES**TREATMENT**

- The treatment is challenging due to the environmental cyst contamination which causes relapses and because giardiasis is often linked to an underlying condition. Recommended treatments consist of daily administrations of metronidazole, or certain benzimidazoles (fenbendazole, oxfendazole, febantel) during at least 3 weeks.
- The treatment should be completed by thorough environmental cleaning and disinfection to decrease the number of cysts.

PREVENTION

Prevention is based on hygienic measures: keeping cages clean, frequent removal of faecal matter and disinfection of floors.



CAT ENDOPARASITES

DIGESTIVE
PROTOZOANS

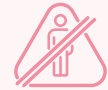ISOSPORA COCCIDIA

Isospora felis, *Isospora rivolta*



Oocysts
(in faeces)
38-51
× 27-39 µm
(*I. felis*)

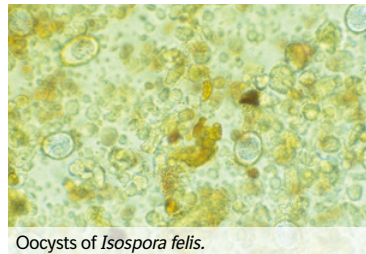
Oocysts
(in faeces)
21-28
× 18-23 µm
(*I. rivolta*)




Visible under the microscope



- *Isospora* spp. are protozoans belonging to the class Apicomplexa and sub-class of Coccidia, grouping intestinal parasites.
- Isosporosis is **common in cats**, especially in young cats.
- *Isospora* spp. sporozoites multiply in the intestinal tract of cats by invading intestinal cells.
- Infected cats shed oocysts in their faeces for a limited period of time.
- Oocysts are very resistant in the environment where they can survive for 1 to 2 years. They must undergo sporulation to become infective.



Oocysts of *Isospora felis*.

**BIOLOGY AND MODE OF INFECTION**

- **Ingestion of sporulated oocysts** from a contaminated environment.
- The ingested oocyst contains 2 sporocysts, each containing 4 sporozoites. The **sporozoites invade the intestinal cells** and undergo an **asexual multiplication** (= schizogony). The infected cells die and expulse thousands of new sporozoites that will repeat the same action.
- After the schizogony phase, **sexual multiplication occurs** (= gametogony) to form oocysts which are excreted in the cat's faeces.
- The infection is followed by immunity.

CLINICAL SIGNS

- Asymptomatic form.
- **In clinical forms**, the initial symptoms may appear at around 3 weeks of age and are often observed after a stress (weaning, sale, transport). Clinical signs are more severe in animals with impaired immunity:
Gastro-intestinal disorders: foul-smelling, mucoid-to-haemorrhagic diarrhoea, abdominal pain, anorexia.
General disorders: poor general condition, weight loss, dehydration, stunted growth.

DIAGNOSIS

Based on the **detection of oocysts in the faeces**, which is relatively sensitive using coproscopy with a **floatation technique**.

CONTROL MEASURES**TREATMENT**


- Treatment consists in the administration of **anti-coccidial drugs** like sulphonamides (e.g., sulfadimethoxine, combinations of trimethoprim and sulfadiazine), toltrazuril or diclazuril.
- A **symptomatic treatment** is also added (rehydration...).

PREVENTION

Prevention is limited in cats and is based only on hygienic measures to eliminate oocysts in the environment.

DIGESTIVE
PROTOZOANS

TOXOPLASMA ^{1/2}
Toxoplasma gondii



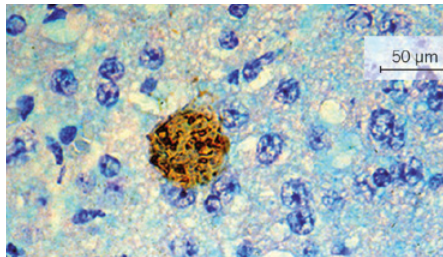
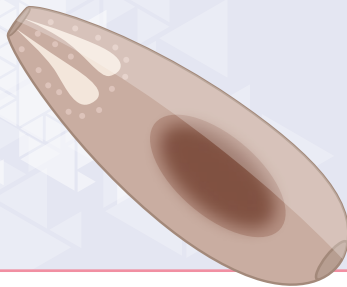
Tachyzoites
(in host cells)
5-6 × 2-3 μm



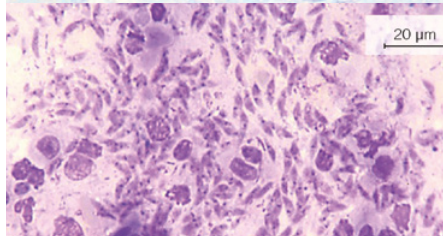
Oocysts
(in faeces)
12-15 × 10-13 μm



Visible under the microscope

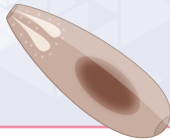

Cyst with bradyzoites. H&E staining. Brain histology.



Toxoplasma gondii pseudocysts: intense tissular multiplication. Tissue smear from an infected kangaroo.

- *T. gondii* is an Apicomplexa protozoan belonging to the order Coccidiorida, which includes coccidia of veterinary and medical importance.
- **Cats are usually infected at a young age:** epidemiological surveys indicate that 1-2 % of cats under 1 year old excrete *Toxoplasma* oocysts.
- ***Toxoplasma* infection is widespread and leads to two distinct clinical entities:**
 - **Toxoplasmic coccidiosis in the definitive host (cats and other felids)**, where the sexual reproduction of the parasite occurs in the intestinal cells only.
 - **Toxoplasmosis in intermediate hosts (mammals and birds) harbouring asexual forms that are non-cell specific:**
 - Bradyzoites located in tissue cysts. They have a slow multiplication but are resistant and persist in the organism.
 - Tachyzoites in pseudocysts. They multiply rapidly and are responsible for the clinical expression of toxoplasmosis.
- **Cats may be both definitive or intermediate hosts** and can present with toxoplasmic coccidiosis and toxoplasmosis at the same time.

DIGESTIVE
PROTOZOANS

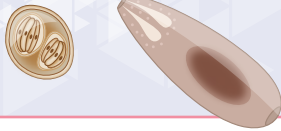BIOLOGY AND MODE OF INFECTION

- **Infection occurs in 3 ways:**
 - Ingestion of **sporulated oocysts** from contaminated food or water.
 - Ingestion of **meat** from intermediate hosts or predation (e.g., rodents).
 - **In utero contamination** of the fetus, in non-immune females infected during gestation.
- **Enteric-epithelial cycle:** In cats and felids following the ingestion of sporulated oocysts from a soiled environment, or of intermediate hosts harbouring cysts. This phase occurs in enterocytes. It includes schizogony (multiplication) and merogony (sexual reproduction) leading to the production of oocysts. When a cat gets infected through the ingestion of an intermediate host, the merogony phase is immediate and oocyst shedding starts earlier (4-6 days) than in cases of direct oocyst ingestion (15-20 days). Oocysts eliminated in the faeces are not immediately infective. They are indistinguishable from those of other coccidian genera (*Isospora*, *Hammondia*, *Besnoitia*).
- **Exogenous phase:** This phase occurs in the environment, oocysts sporulate and become infectious in 48h to 5 days. They are very resistant and can infect cats or intermediate hosts including humans.
- Oocyst excretion by cats takes place during the primary *Toxoplasma* infection but may also occur after the reactivation of cysts due to a transient immunosuppression or infection by other species of coccidia (*Isospora* spp.).



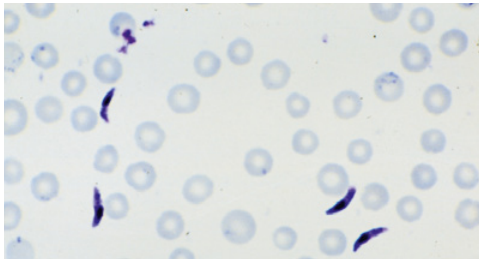
CLINICAL SIGNS

- **In the definitive host: Toxoplasmic coccidiosis.** Most cats do not show any signs. Sometimes a mild diarrhoea can be observed.
- **Primo-infection in intermediate hosts: Toxoplasmosis.**
 - The infection is **often asymptomatic in immunocompetent hosts.** If present, signs can vary widely:
 - Fever, fatigue, and lymph nodes enlargement.
 - **Respiratory forms** with bronchopneumonia and irregular fever.
 - **Nervous forms** similar to distemper in dogs with central and peripheral disorders like seizure, epilepsy, and paresis.
 - **Acute and lethal forms** in immunosuppressed or highly sensitive intermediate hosts like **marsupials.**
 - **In pregnant mammals** (especially sheep and humans, but also dogs), the tachyzoites can reach the foetus and lead to **abortion or mortinatality.**

**DIAGNOSIS**

The diagnosis never relies only on clinical signs, it is based on laboratory confirmation.

- **Direct methods:** In case of clinically expressed progressive toxoplasmosis
 - Centrifugation and staining of lymph aspirate, bone marrow, bronchoalveolar lavage, etc., followed by microscopic observation.
 - Intra-abdominal injection of the sample into a sensitive mouse and examination of the ascitic fluid 2-5 days later, looking for tachyzoites.
 - PCR to detect *Toxoplasma* DNA is a sensitive method.
- **Indirect method: Serology** (e.g., ELISA, hemagglutination) to detect antibodies is the **fastest and easiest method**. Antibodies appear within 3 weeks post-infection, but positive results do not mean that there is an active *Toxoplasma* infection. **IgM are a sign of recent infection, whereas IgG are detectable for years** and may indicate an older infection depending on the titers.




Toxoplasma gondii tachyzoites. MGG staining.
Collection in ascites of an infected mouse.

ZOOONOTIC RISK

- Toxoplasmosis is a **major zoonosis** in which the veterinarian plays an essential role in safeguarding public health.
- The serological prevalence in humans worldwide varies from 10% to 80%, depending on the geographic location.
- Human congenital toxoplasmosis is the **most frequent congenital disease after Down's syndrome**. Infection during the **first trimester of pregnancy** may cause toxoplasmic meningoencephalitis (**macrocephaly, hydrocephaly, ocular and nervous problems**). For the **remaining two trimesters**, infection causes **fatal visceral forms or delayed forms** which are only visible after birth (e.g., chorioretinitis, developmental delay).
- **Soiled vegetables or contaminated meat** consumption (especially pork or lamb) is the **main route of infection** for humans.





CONTROL MEASURES

TREATMENT

- The toxoplasmosis treatment **aims at stopping the tachyzoites multiplication**. Oral clindamycin is used daily for 4 to 6 weeks.
- Non-digestive forms (e.g., respiratory or nervous signs) require **complementary symptomatic treatments**.

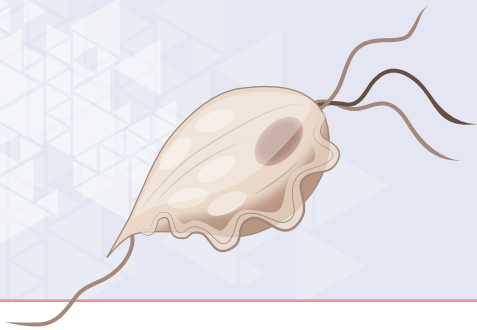PREVENTION

It is difficult as infected cats are often asymptomatic, and the excretion of oocysts is unpredictable.

- **In cats**
 - Preventing cats from preying on intermediate hosts such as mammals or birds and feeding them with commercial diets or well-cooked meat will reduce the risk of contamination.
 - Medical prevention is not recommended: anti-coccidia sulfamides are only active against the pathogenic forms and not the oocysts. They cannot be used as a prophylaxis.
- **In humans**
 - Soiled/contaminated food consumption being the main route of infection for humans, the prevention relies on washing/boiling vegetables and ensuring that the meat is well cooked to the center.
 - Pet cat's faeces from the litter may also be a source of infection. It is therefore recommended for cat owners to clean the litter daily, to remove oocysts that could have been shed before they get infective. Wearing gloves is an additional hygiene measure.



Raw meat diet must be avoided in cats.




CAT ENDOPARASITES

DIGESTIVE PROTOZOANS

TRITRICHOMONAS

Tritrichomonas blagburni (formerly *T. foetus*)



Mobile stages
7-10 x 10-15 μ m

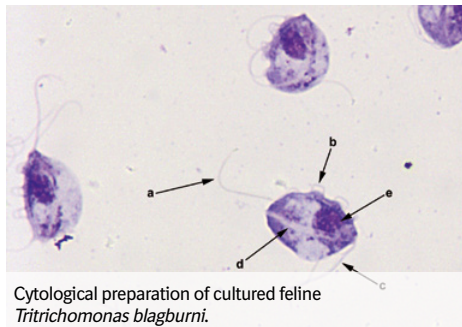


Visible under the microscope

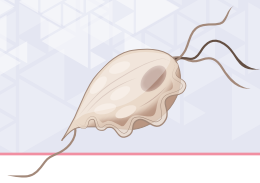
No cysts



- *Tritrichomonas blagburni* (formerly *T. foetus*) are Trichomonads, i.e., flagellate protozoans.
- They are found in the superficial mucus and in contact with the epithelium surface of the distal ileum and colon of cats.
- Young cats and cats living in collectivity (e.g., catteries) are usually more sensitive to *T. blagburni* infection.



Cytological preparation of cultured feline
Tritrichomonas blagburni.



DIGESTIVE PROTOZOANS

TRITRICHOMONAS

Trichomonas blagburni (formerly *T. foetus*)

BIOLOGY AND MODE OF INFECTION

- Ingestion of *Trichomonas* infective stages from faecal-contaminated matters (water, food, fomites), or through self-grooming.
- The protozoans multiply directly on the intestinal epithelium, and stay as a flagellate active form. There is no production of cysts.

CLINICAL SIGNS

- Most cats are asymptomatic carriers and do not show any signs.
- In case of clinical infection:
 - Waxing, waning, malodorous and 'cow pat' consistency diarrhoea, which often contains fresh blood and mucus.
 - Faecal incontinence, swelling and inflammation of the anal region in kittens.
 - Highly painful defecation.

DIAGNOSIS

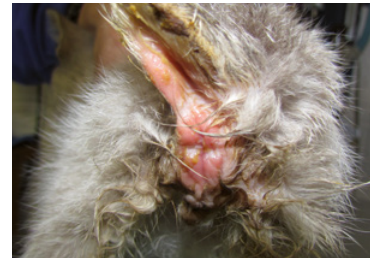Based on the identification of the flagellate by:

- Direct faecal smear examination in a drop of water to see the flagellates moving.
- Culturing the faeces in media promoting the growth of *Trichomonas* spp. (pouch system as used for *T. vaginalis* in human health) may be used to enhance the detection of the protozoan.
- PCR from a faecal sample.

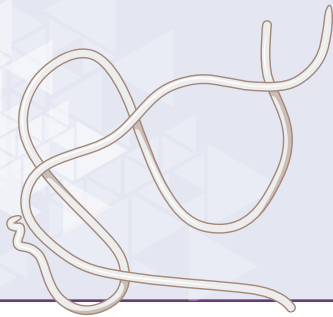CONTROL MEASURES

TREATMENT

- No specific license exists for the treatment of trichomonosis, but ronidazole has been demonstrated to be effective. However, ronidazole may induce adverse events (e.g., lethargy, inappetence, ataxia, seizures) so cats must be monitored closely during the treatment.
- Prevention of the infection is based on hygienic measures.



Faecal incontinence and inflammation of the anus in a kitten with trichomonosis (colitis and chronic diarrhoea).

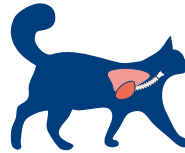


CAT ENDOPARASITES

VECTOR-BORNE DISEASE

HEARTWORM

Dirofilaria immitis



Adults
(at necropsy)
10-15 cm

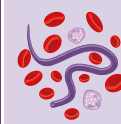


Visible with
naked eye

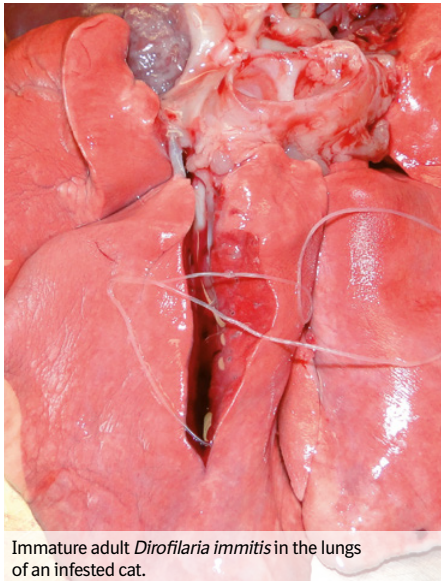
Microfilariae
0.29-0.33 mm



Visible under
the microscope



(extremely rare)



Immature adult *Dirofilaria immitis* in the lungs of an infested cat.

- Dirofilariasis is enzootic in the Americas, in warm and humid areas of Europe, Asia and Africa, and in the Southern hemisphere.
- Adult *Dirofilaria immitis* worms are filarial nematodes that measure 10 to 15 cm long. They live in the **pulmonary arteries and right heart ventricle** of dogs and other mammals including cats.
- **The cat is an atypical host for heartworms** and most worms die before reaching the adult stage without being detected.
- Infested cats usually harbour only one to three adult heartworms. As a result, the disease is **often undiagnosed**, as based on female antigen and microfilariae detection.
- Immature worms can cause damage in the lung arteries before their elimination or development. Adult worms survive for 2 to 4 years: when they die, the inflammation can be severe enough to cause the cat's death.



BIOLOGY AND MODE OF INFESTATION

Dirofilaria immitis third stage larvae are deposited on the skin by female mosquitoes (*Aedes*, *Culex*, *Anopheles* genera) during a blood meal. The larvae penetrate the skin through the bite wound, migrate through the tissues and then enter a blood vessel. The immature worms are carried to the lung arteries where they cause an inflammatory reaction. The complete development in cats takes around 9 months, when it takes 6 months in dogs.

CLINICAL SIGNS

Cats may be **asymptomatic** or develop clinical signs of variable intensities. Feline heartworm disease is recognised as a **significant pulmonary syndrome**, with two distinct phases:

- **Initial phase, 2 to 3 months after infestation:** coughing, dyspnea, vomiting, related to inflammatory immune response to the immature forms reaching the lung arteries. Thanks to this reaction, many cats are cleared from heartworms at that stage. Other cats with surviving heartworms will later enter the second phase.
- **Second phase of the disease** (typically 1 to 3 years after infestation, when adult worms die): pulmonary inflammation and thromboembolism, with severe cardiopulmonary symptoms, leading to sudden death (~20%) or self-cure (~80%).

DIAGNOSIS

It is harder in cats than in dogs as they are less likely to harbour adult heartworms.

- **Imaging:** X-rays, echocardiography (visualisation of the parasite).
- **Laboratory diagnosis:** detection of microfilariae (blood smear) and antigen test: they are often falsely negative, due to the low number or absence of female worms. Combining them with antibody tests may allow to detect more infested cats.

ZOONOTIC RISK

Humans rarely become infested through mosquito bites. The disease is mostly asymptomatic, with pulmonary nodules incidentally detected on chest radiographs.

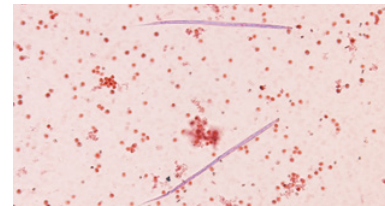
CONTROL MEASURES

TREATMENT

- Heartworm disease treatment of cats with dog-labeled products is very complicated, not recommended, and has a poor prognosis.
- Surgical removal of worms can be performed, for cats with severe disease.

PREVENTION

Monthly administrations of macrocyclic lactones (e.g., eprinomectin, moxidectin, selamectin) **during the mosquito season** are indicated for the prevention of cardiopulmonary dirofilariosis in cats.

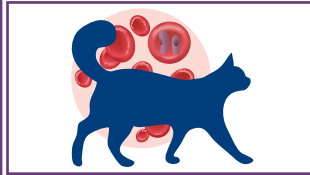
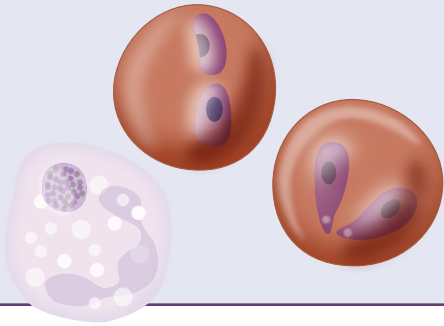


Dirofilaria immitis microfilariae.

VECTOR-BORNE DISEASES

TICK-BORNE PATHOGENS 1/2

Cytauxzoon spp., *Babesia* spp., *Anaplasma* spp., *Ehrlichia* spp., *Rickettsia* spp.



Cytauxzoon spp.
Piroplasms in red blood cells



Babesia spp.
Piroplasms in red blood cells



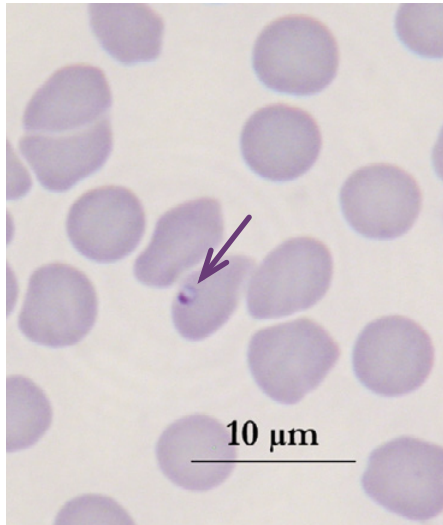
Rickettsial organisms
Bacteria in blood cells



Some rickettsial organisms



Visible under the microscope

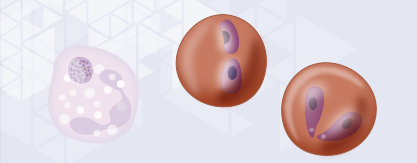


Cytauxzoon sp. (Courtesy from Luc Chabanne).

Cytauxzoon spp. and *Babesia* spp. are protozoans, piroplasms which infect the red blood cells of domestic cats. They are transmitted through a tick bite.

Cytauxzoon spp.

- At least two **different species of *Cytauxzoon* spp.** are known to cause cytauxzoonosis in cats: *C. felis* has been only reported in North and South America for many years, but more recently, *Cytauxzoon* sp. has also been observed in Europe (Spain, France and Italy). The reservoirs of *Cytauxzoon* spp. are wild felids like Bobcats and Lynx.
- The tick vectors are *Amblyomma americanum* in the USA, and probably *Ixodes* ticks in Europe.
- Most cases occur from spring to early autumn.



VECTOR-BORNE DISEASES

CAT ENDOPARASITES

TICK-BORNE PATHOGENS

Cytauxzoon spp, *Babesia* spp, *Anaplasma* spp,
Ehrlichia spp, *Rickettsia* spp.

MODE OF INFECTION

Infection occurs during tick feeding.

CLINICAL SIGNS

Cytauxzoonosis is a **severe disease in the US** with a high death rate, and a **mild disease in Europe**. Surviving animals become asymptomatic reservoirs.

In the USA, *C. felis* infection may be associated with:

- **Severe febrile syndrome:** high fever, depression, anorexia, icterus, dyspnoea, tachycardia, generalised pain and vocalisation.
- **Haemolytic anaemia:** pale mucous membranes, abnormal brownish urine colour.

In Europe, *Cytauxzoon* sp. infections are less virulent than the *C. felis* ones. Febrile syndrome with anaemia is described.

DIAGNOSIS

Based on the **detection of the piroplasm in blood smears** and/or samples of fine needle aspirates from the liver, spleen, and lymph nodes.

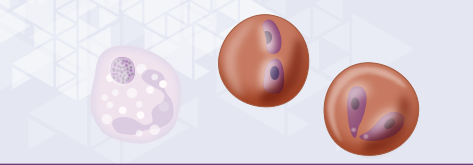
CONTROL MEASURES

TREATMENT

Piroplasmicides are used (e.g., atovaquone, azithromycin) in combination with supportive symptomatic treatments. The prognosis remains poor in the USA.

PREVENTION

Cats with outdoor access in endemic areas should receive effective and regular tick treatment as prevention (see memo card 'Ticks').



Babesia spp.

GENERALITIES

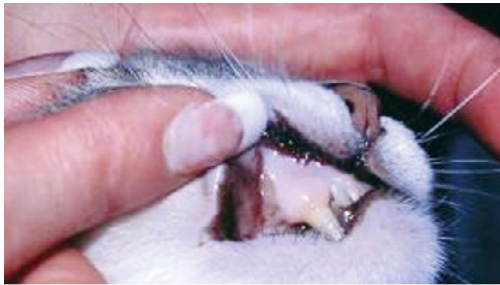Babesiosis in cats is caused by protozoans of the *Babesia* genus (e.g., *Babesia felis*, *Babesia cati*, *Babesia canis presentii*...), **infecting red blood cells** and causing hemolytic anaemia. Cats are less susceptible to babesiosis than dogs and the disease is rare.

MODE OF INFECTION

Babesia spp. are transmitted by different tick species.

CLINICAL SIGNS

Main clinical signs are **febrile syndrome, anaemia and jaundice**.

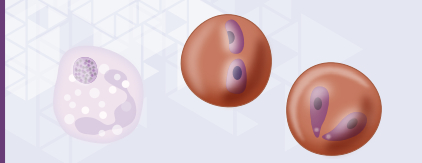


Pale mucous membrane in an anaemic cat.

CONTROL MEASURES

TREATMENT

Treatment and prevention are the same as for *Cytauxzoon* infections.



VECTOR-BORNE DISEASES

CAT ENDOPARASITES

TICK-BORNE PATHOGENS

Cytauxzoon spp., *Babesia* spp., *Anaplasma* spp.,
Ehrlichia spp., *Rickettsia* spp.

Rickettsial infections

Rickettsial agents are small bacteria infecting white blood cells or platelets.

GENERALITIES

Rickettsial infections are caused by *Anaplasma* spp., *Ehrlichia* spp. and *Rickettsia* spp. The **most important** feline pathogen among these organisms is *Anaplasma phagocytophilum*.

MODE OF INFECTION

For the majority of species, **infection occurs during tick feeding**. Vectors are mainly *Ixodes* ticks.

CLINICAL SIGNS

Usually reported in the week following tick infestation. They are often **non-specific**, consisting of fever, anorexia and lethargy. Joint pain may occur.

ZOONOTIC RISK

Some rickettsial species (e.g., *A. phagocytophilum*, *R. conorii*, *R. rickettsii*) are of zoonotic concern.

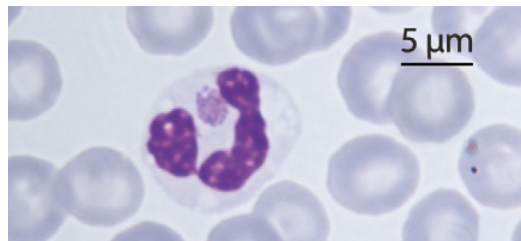
CONTROL MEASURES

TREATMENT

Doxycycline is the first-choice antibiotic for treating anaplasmosis, ehrlichiosis or rickettsioses.

PREVENTION

Cats with outdoor access in endemic areas should receive effective and regular flea and tick treatment as prevention (see memo cards 'Ticks').



Anaplasma phagocytophilum in a white blood cell (neutrophil).

ANTHELMINTIC TREATMENT IN CATS

RECOMMENDATIONS FROM THE ESCCAP GUIDELINE 01 EDITION MAY 2021



DESCRIPTION	RECOMMENDED DEWORMING FREQUENCY
KITTENS	From 3 weeks of age: every 2 weeks until weaning and then monthly until 6 months of age.
ADULT CATS	
Cat living indoor; worm pressure is low, eating rodents unlikely	Deworm 1-2 times/year against nematodes*
Cat free to roam; worm pressure is high, eating rodents likely	Deworm against nematodes and tapeworms at least 4 times/year*
Cat eating prey animals and/or going outdoors to hunt and/or eats raw meat	Deworm against nematodes and tapeworms more than 4 times/year*
Cat free to roam and sharing home with young children (< 5 years-old) or immunocompromised people	Deworm once-a-month*

*Or perform a faecal examination at the same frequency and treat according to the results



parasit'**Xpert**TM



ISBN : 978-2-9550805-6-6
EAN : 9782955080566